

Intractable Neuropathic Pain in Spinal Intramedullary Cavernoma Treated Successfully with a Novel Combination Cream

No grants or other forms of support were given.
The authors declare no (financial) conflict of interest.

To the Editor:

Herein, we report our successful use of a compounded cream to treat a patient with neuropathic pain due to an old hemorrhage caused by a spinal intramedullary cavernoma, resistant to oral analgesics.

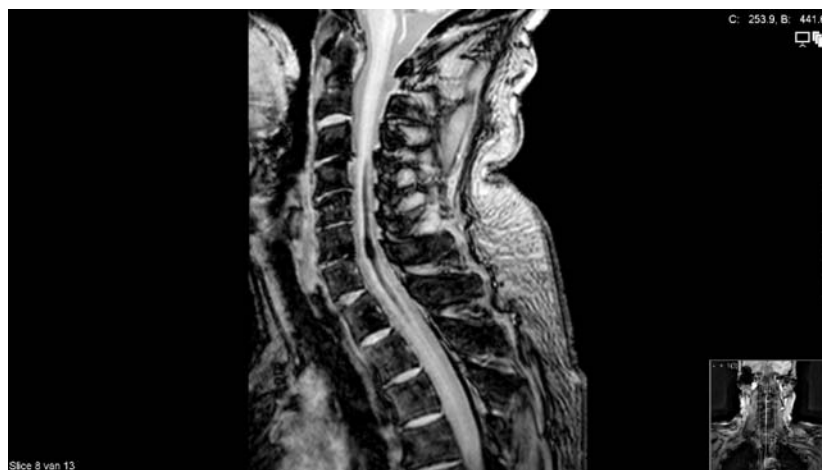
In July 2004, a 63-year-old man faced a sudden onset of burning pain in his right armpit, upper back, and neck after strenuous rotational movement of the thorax. Soon tingling in his right arm and numbness and weakness in his legs developed. Diminished sensibility for touch, pinprick, warmth, and cold at the right side, from Th12 downward was found. Magnetic resonance imaging (MRI) showed a cystic process extending from C4 until Th2. Slowed conduction velocities were present in C5. Syringomyelia was diagnosed by two different neurosurgeons. The patient refused surgery because of potential for complications. Six years later, the diagnosis was revised. On a weighted T2 MRI, no cavity was visible in the spinal cord; however, an intramedullar lesion with low intensity suggested old hemorrhage from an intramedullary cavernoma (see Figure 1).

Treatment with amitriptyline (75 mg daily) was stopped due to side effects, and capsaicin 0.025% cream worsened the burning pain. Gabapentin 1800 mg and dulox-

etine 30 mg daily diminished the pain on the 11-point numerical rating scale (NRS) from 10 to 6. Higher doses were not tolerable. In October 2009, the patient was seen at our institute, and we prescribed a combination cream consisting of 0.075% capsaicin, 3% lidocaine, and 0.4% isosorbide dinitrate (ISDN). After 1 month, the pain decreased on the NRS from 6 to 3. There were even days without pain. After 3 months, he continued to use only the capsaicin cream once a day. Within 6 weeks, burning pain re-emerged. Then, he resumed the use of the combination cream, and again his pain score decreased by 50%.

Central neuropathic pain in this case, due to an old hemorrhage from a spinal intramedullary cavernoma, is characterized by a lesion of the spinothalamic tract, usually resulting in thermosensory deficits, also seen in syringomyelia [1]. The pathophysiology of central neuropathic pain is a complex mechanism, in which the lesion triggers molecular changes in nociceptive neurons that become abnormally sensitive and develop pathological spontaneous activity [2]. In turn, this hyperactivity induces hyperexcitability in processing neurons in the spinal cord and brain. Monotherapy is usually not sufficient to treat effectively central neuropathic pain. Most studies indicate that optimal drug treatment results in one-third of all patients having a 50% reduction in pain intensity [3]. Side effects very often limit dose titration into the upper dosage ranges. Rational polytherapy is therefore a logical strategy with a higher likelihood of success, usually with fewer side effects [4]. In cases of severe intractable pain, a trial-and-error treatment process should be considered [5].

Figure 1 T2-weighted MR image sagittal plane: hypointense intramedullary lesion from C3 until Th2, with the main lesion at C6/C7.



In our case, a hint for the pain-relieving solution was given; at the moment, his burning pain was aggravated by the 0.025% capsaicin cream. As capsaicin activates and sensitizes C-nociceptor afferents, worsening of the burning sensation implies the anatomical and functional integrity of some C-nociceptive pathways in this patient [6,7]. Using analgesic substances before the application of capsaicin reduced burning and also provided direct relieve of the pain. This combination cream has multiple mechanisms of action. Capsaicin causes desensitization of the sensory C-fibers, via the TRPV-1 receptor by depleting substance P from the nerve terminals in the dorsal horn [8]. The primary mechanism of action of lidocaine is the inhibition of voltage-gated sodium channel in peripheral nerves [9]. ISDN, as a nitric oxide (NO) donor, has analgesic and vasodilatory properties [10]. Both lidocaine and ISDN reduce the burning side effect of capsaicin.

In conclusion, combination of topical analgesics can be considered in the treatment of central neuropathic pain.

DAVID JOS KOPSKY, MD
Director Clinical Operations
The Institute for Neuropathic Pain
Amsterdam, The Netherlands

GERRIT JOHAN AMELINK, MD, PhD
Neurosurgeon, Associate Professor of Neurosurgery
Department of Neurology and Neurosurgery
University Medical Center Utrecht
Utrecht, The Netherlands

JAN MARIUS KEPPEL HESSELINK, MD, PhD
Professor of Pharmacology
Department of Pharmacology and Toxicology
University of Witten/Herdecke, Germany
Director Research & Development
The Institute for Neuropathic Pain
Bosch en Duin, The Netherlands

References

- 1 Ducreux D, Attal N, Parker F, Bouhassira D. Mechanisms of central neuropathic pain: A combined psychophysical and fMRI study in syringomyelia. *Brain* 2006;129:963–76.
- 2 Baron R. Neuropathic pain: A clinical perspective. *Handb Exp Pharmacol* 2009;194:3–30.
- 3 Siddall PJ. Management of neuropathic pain following spinal cord injury: Now and in the future. *Spinal Cord* 2009;47:352–9.
- 4 Backonja MM, Irving G, Argoff C. Rational multidrug therapy in the treatment of neuropathic pain. *Curr Pain Headache Rep* 2006;10:34–8.
- 5 Jensen TS, Finnerup NB. Management of neuropathic pain. *Curr Opin Support Palliat Care* 2007;1:126–31.
- 6 Schmeltz M, Schmidt R, Weidner C, et al. Chemical response pattern of different classes of C-nociceptors to pruritogens and algogens. *J Neurophysiol* 2003;89:2441–8.
- 7 Wasner G, Lee BB, Engel S, McLachlan E. Residual spinothalamic tract pathways predict development of central pain after spinal cord injury. *Brain* 2008;131:2387–400.
- 8 Szolcsányi J. Forty years in capsaicin research for sensory pharmacology and physiology. *Neuropeptides* 2004;38:377–84.
- 9 Cummins TR, Sheets PL, Waxman SG. The roles of sodium channels in nociception: Implications for mechanisms of pain. *Pain* 2007;131:243–57.
- 10 Yuen KC, Baker NR, Rayman G. Treatment of chronic painful diabetic neuropathy with isosorbide dinitrate spray: A double-blind placebo-controlled cross-over study. *Diabetes Care* 2002;25:1699–703.